

Figure 2: Coin in proximal esophagus/thoracic inlet. Circular on AP view

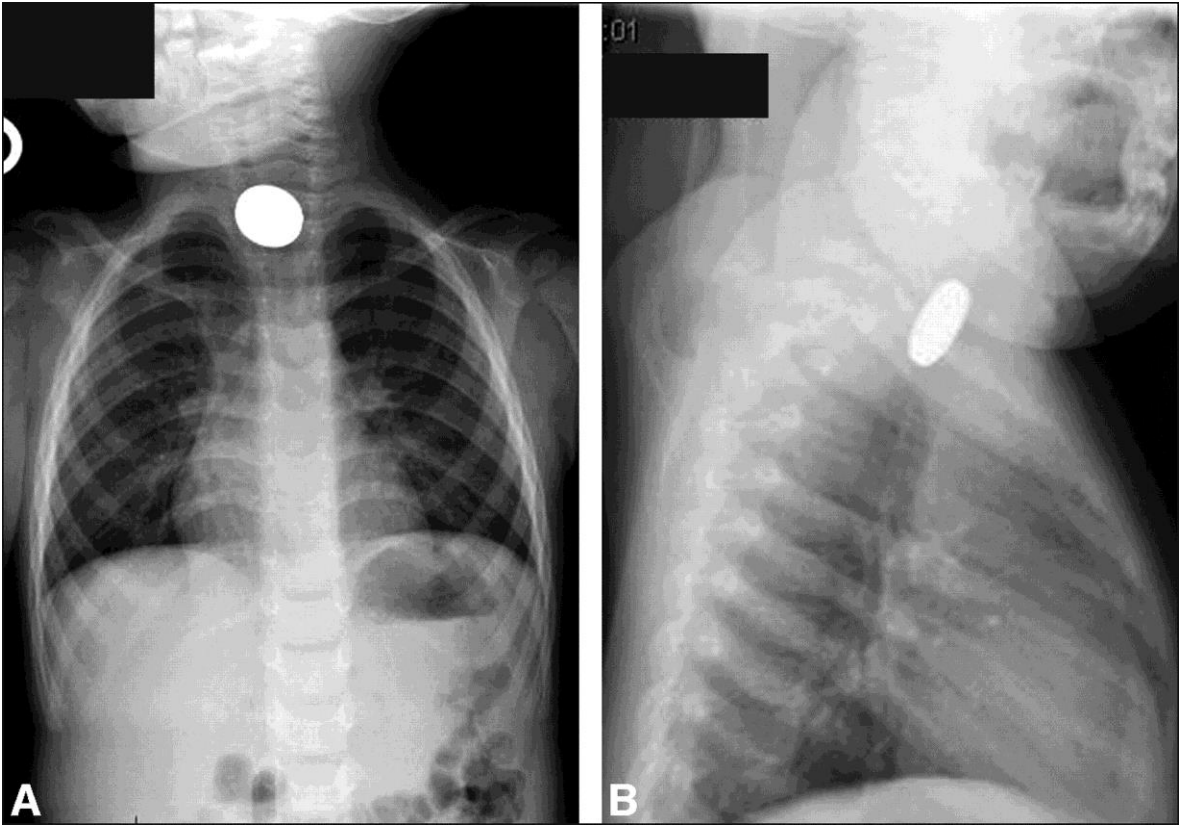


Figure 3: Coin in trachea. Circular on lateral view

